
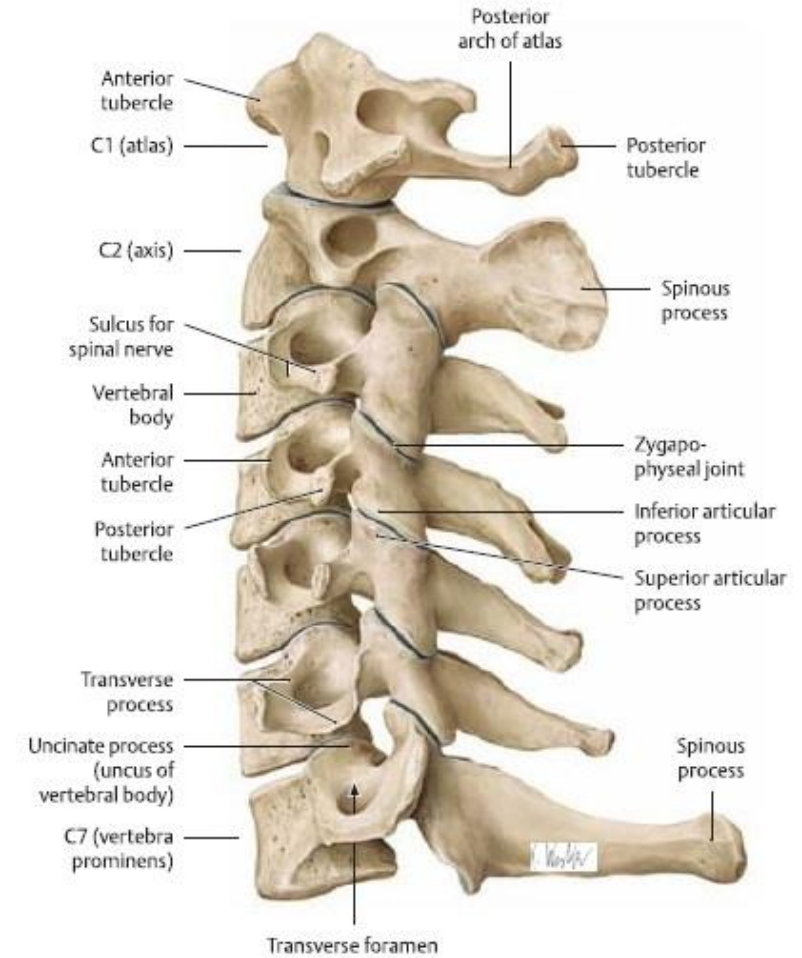
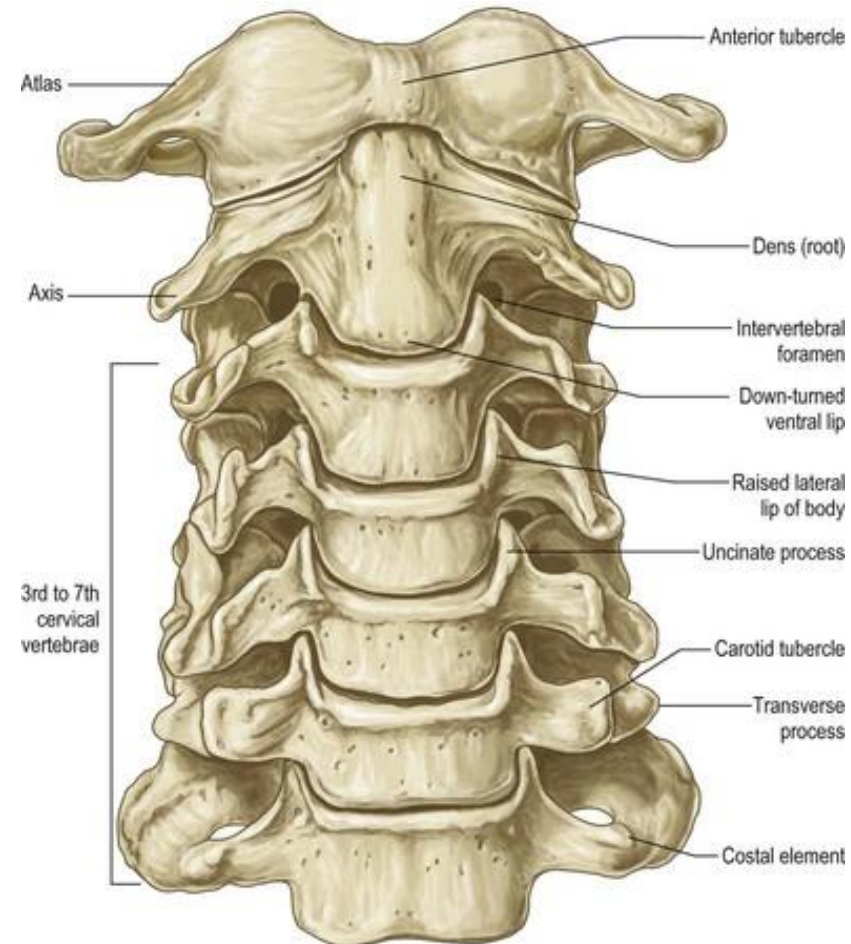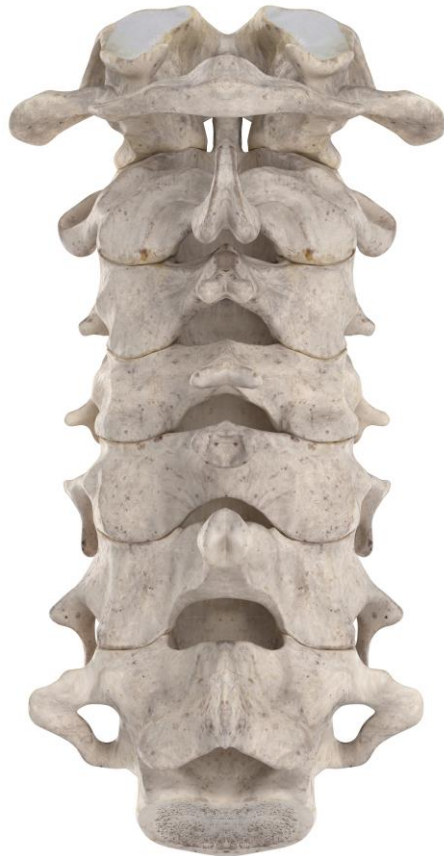


Relieving Painful Cervical Spine (neck) Problems

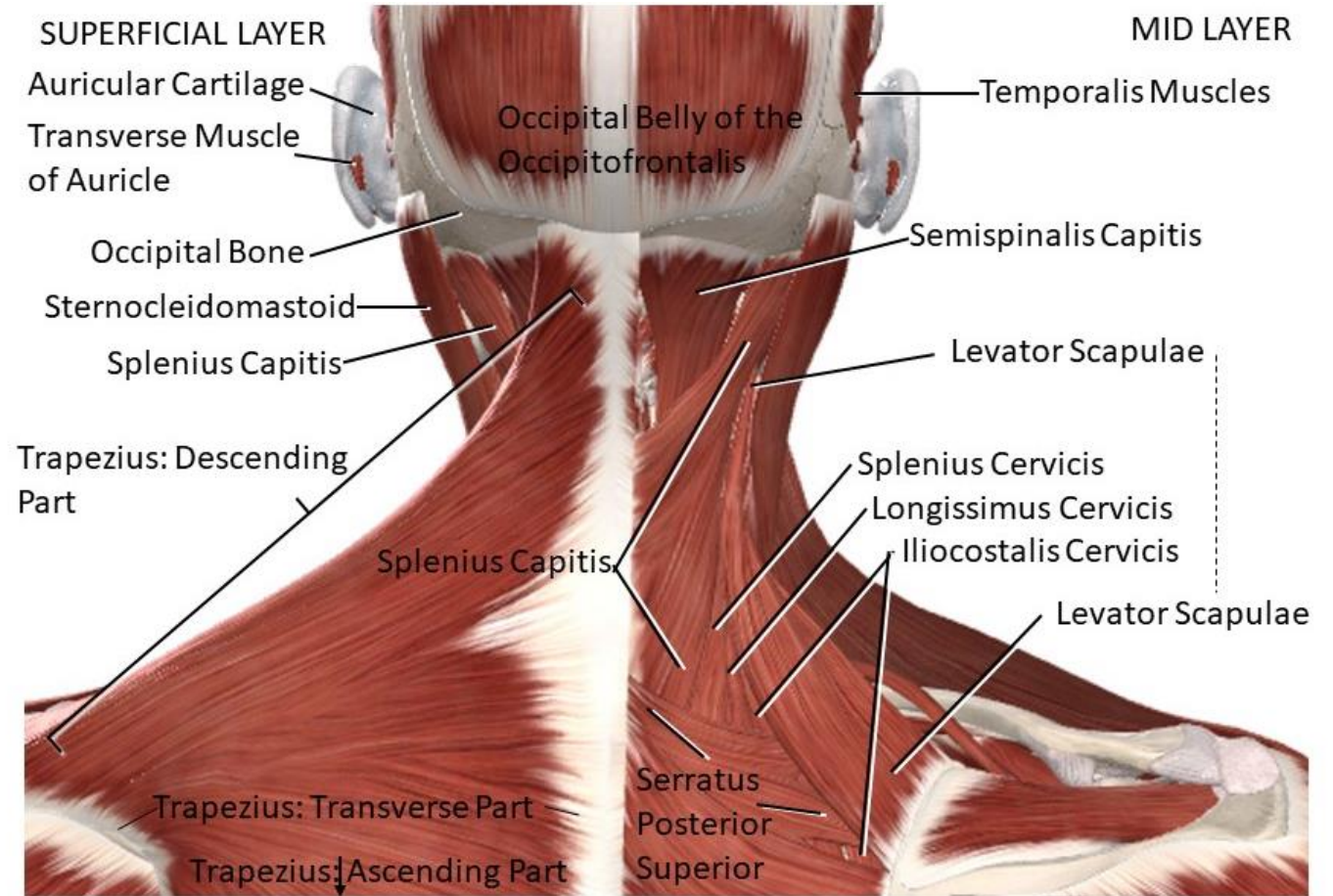
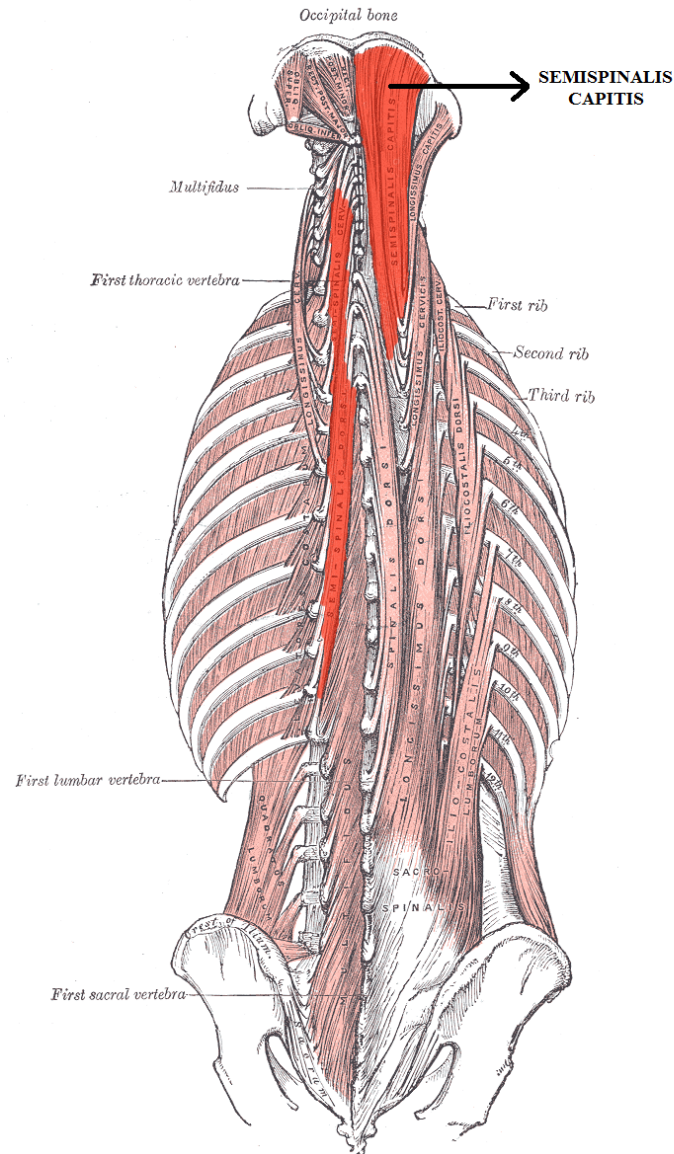
Robert Harper, MD
BoulderCentre for Orthopedics & Spine
720-442-0419



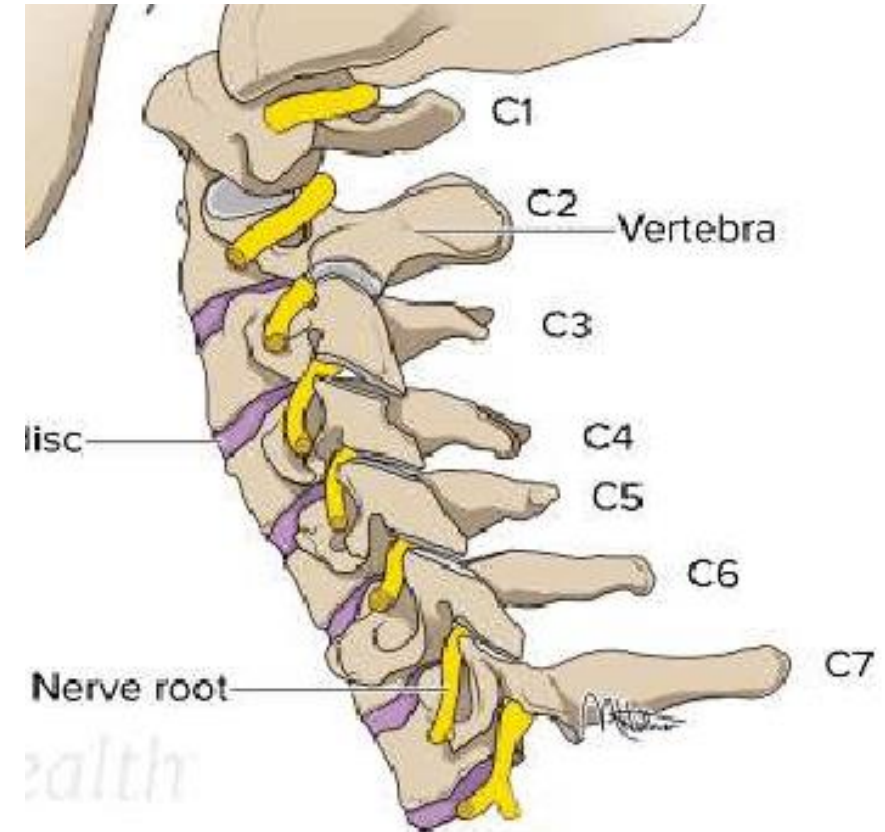
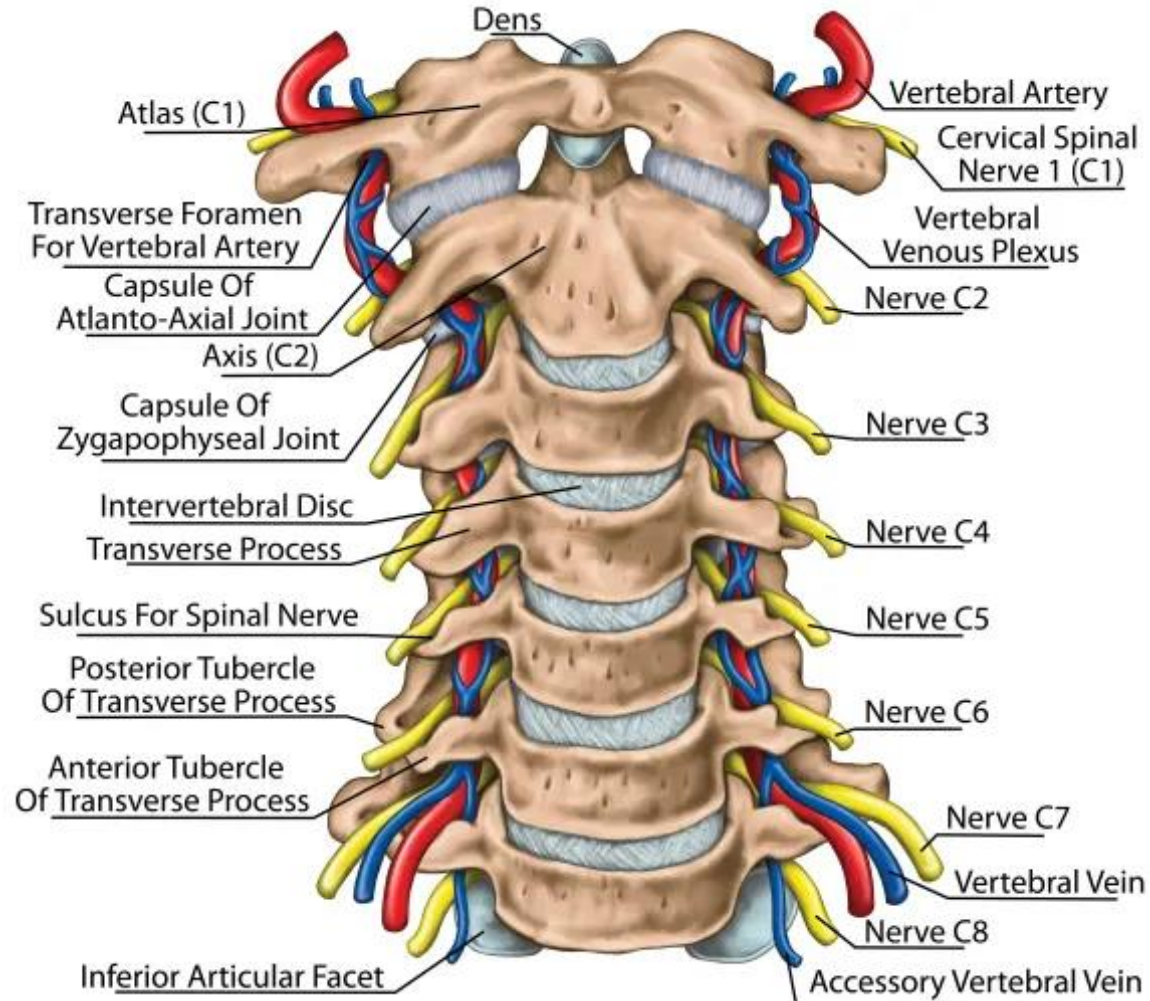
Anatomy of the Neck



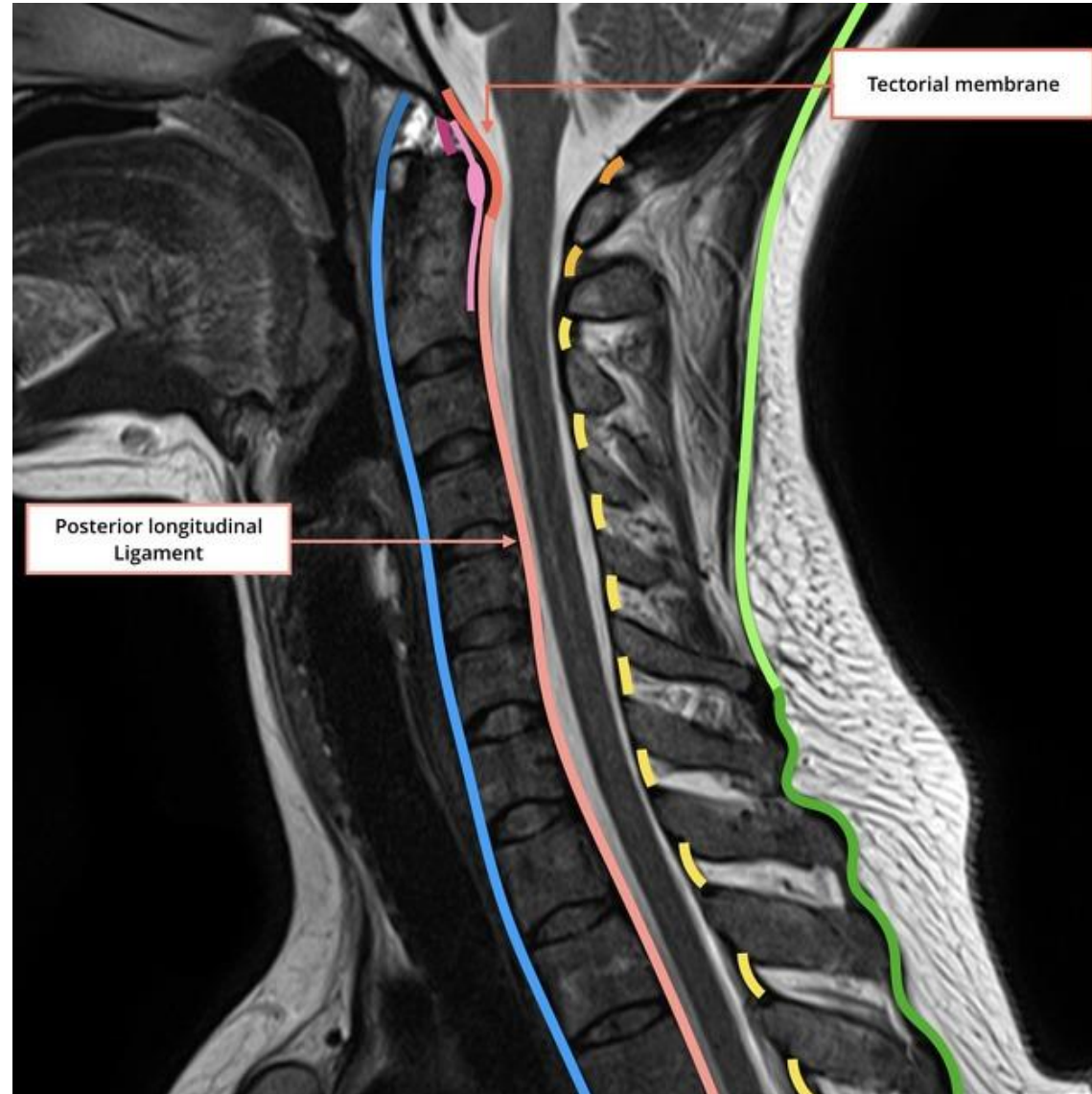
Anatomy of the Neck



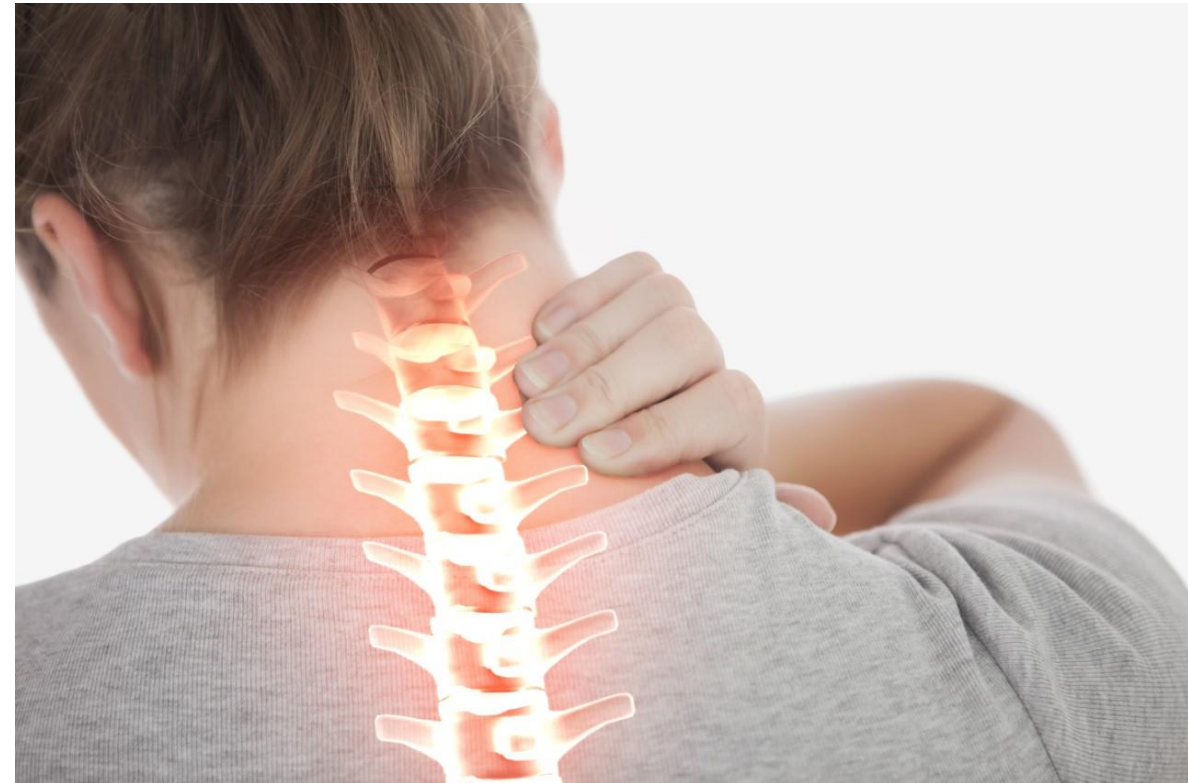Anatomy of the Neck



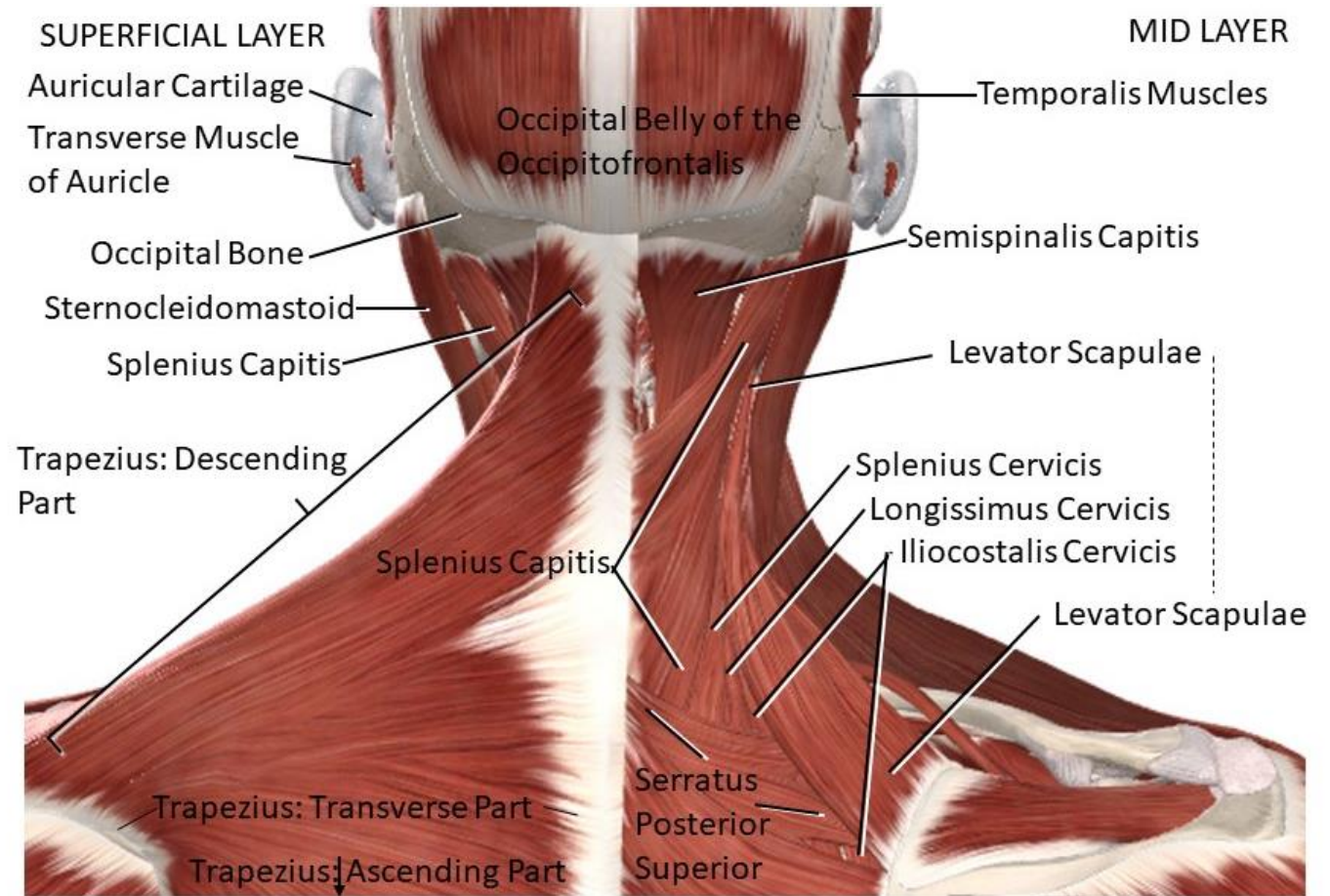
Anatomy of the Neck



- Very common condition
- Can be related to arthritis, muscle spasm or nerve pinching
- Symptoms:
 - Pain in the back of side of the neck with movement
 - Can be on only one side
 - May also have shoulder pain

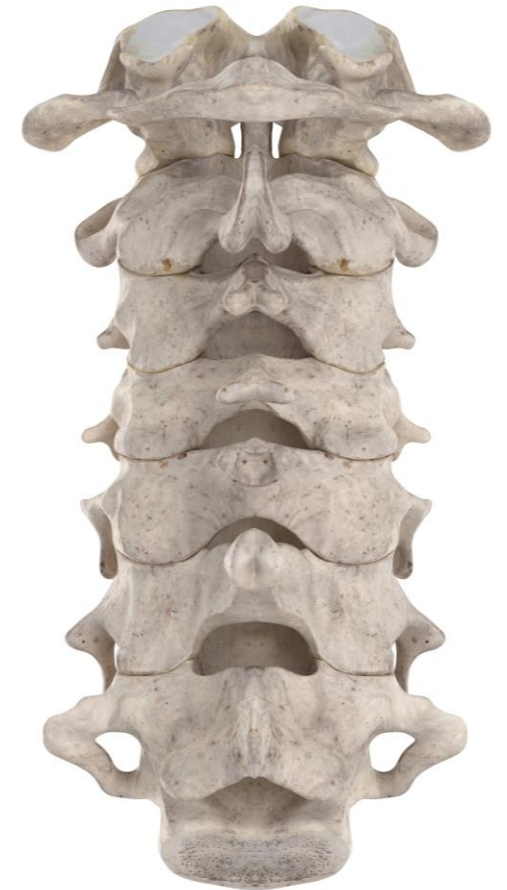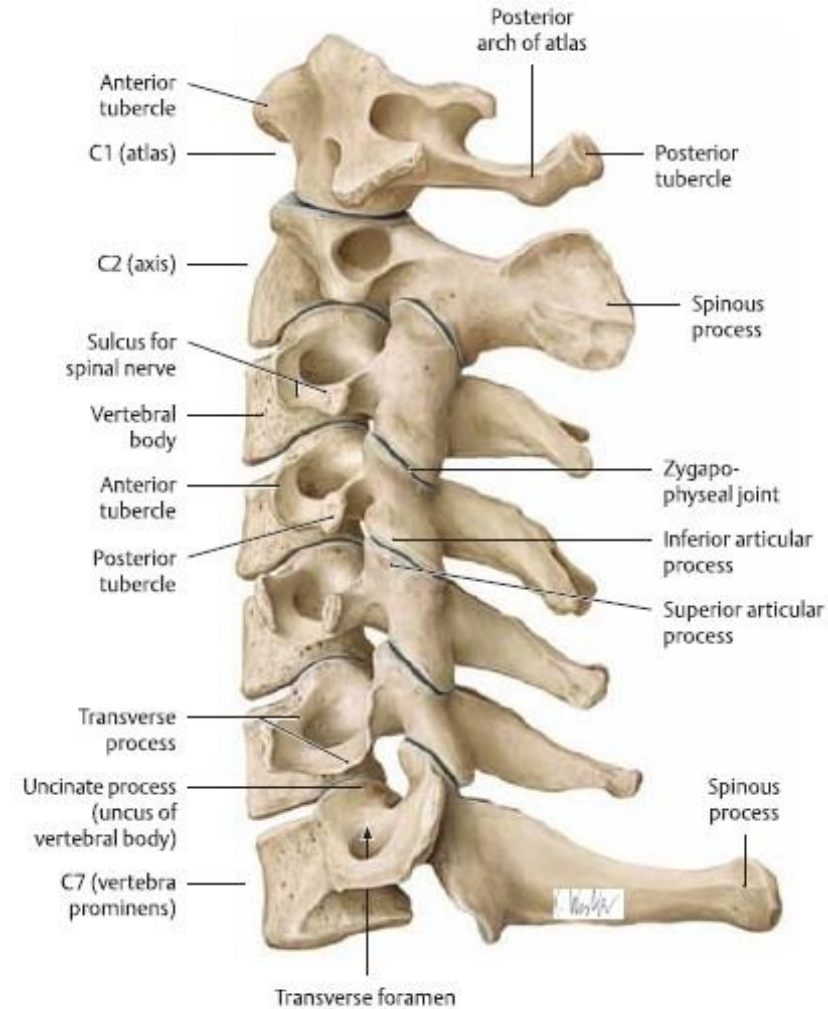


- Multiple origins:
 - Trapezius, torticollis, etc.
 - Can be radiculopathy
- Treatments:
 - Dry Needling, botox, PT, massage

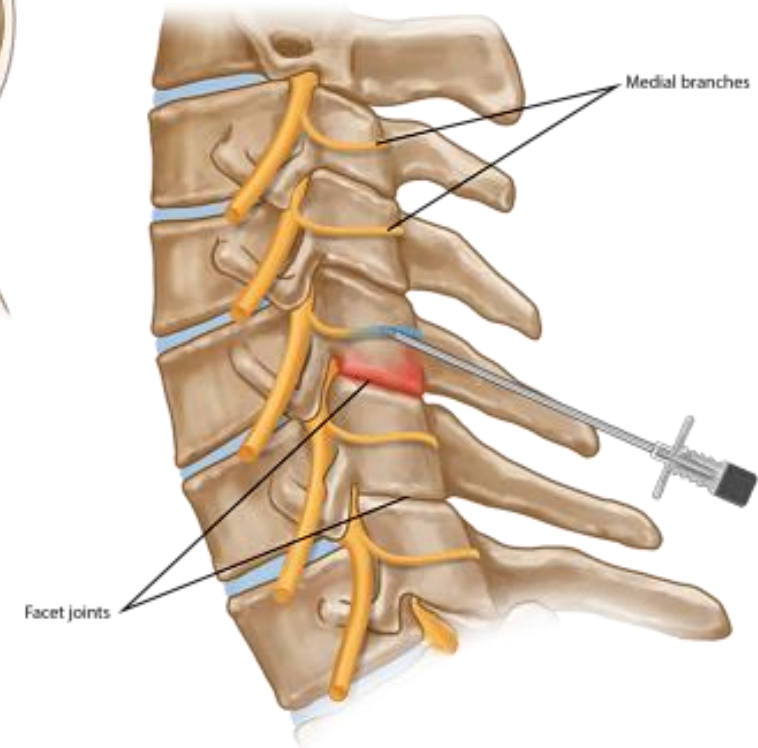
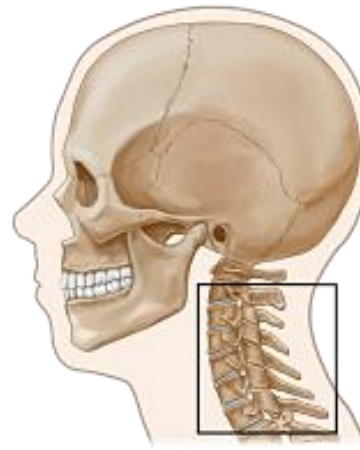


Facet Arthritis

- Degradation of neck joints
- Symptoms:
 - Pain when turning head or with motion
 - Can be on only one side
 - May also have shoulder pain

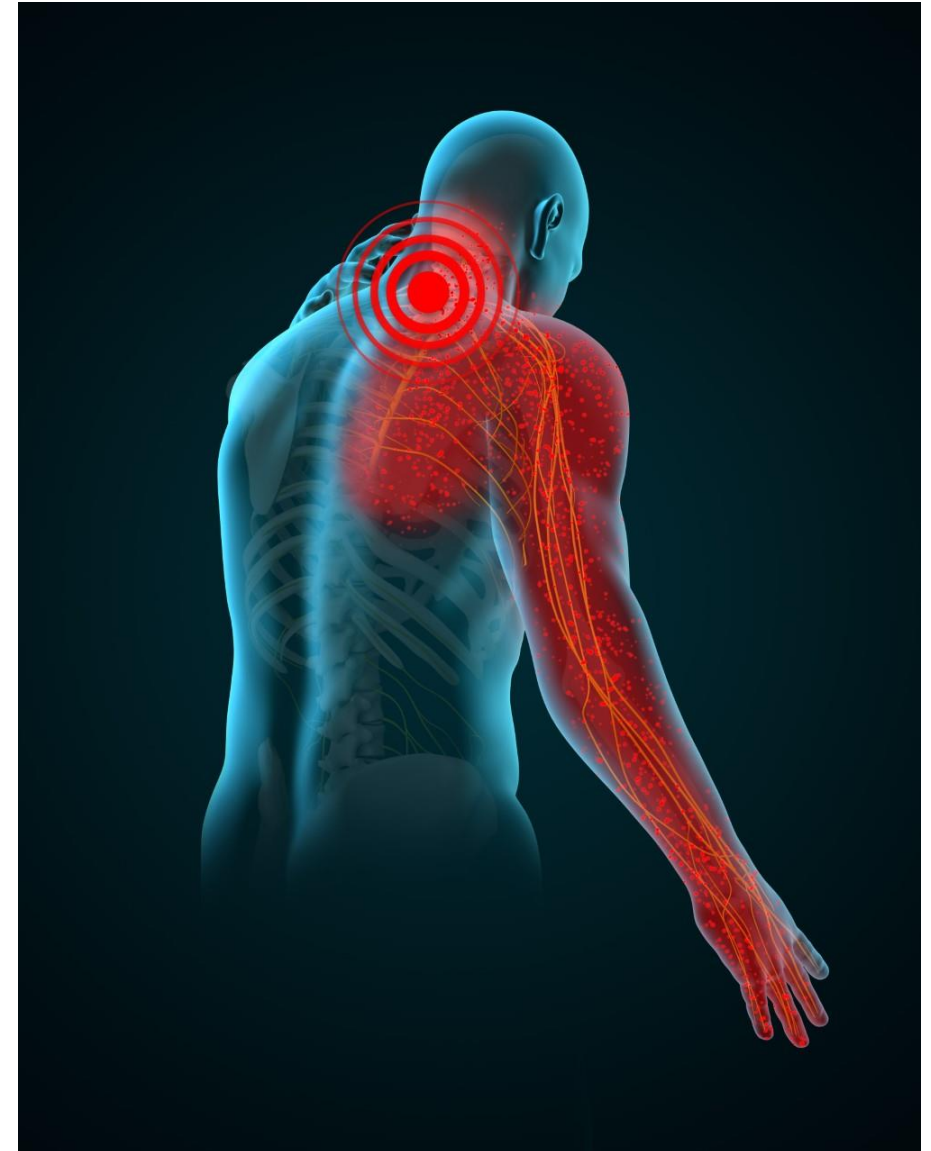

- Treatments:
 - Physical Therapy, massage, dry needling, chiropractic
 - Facet injections, facet blocks



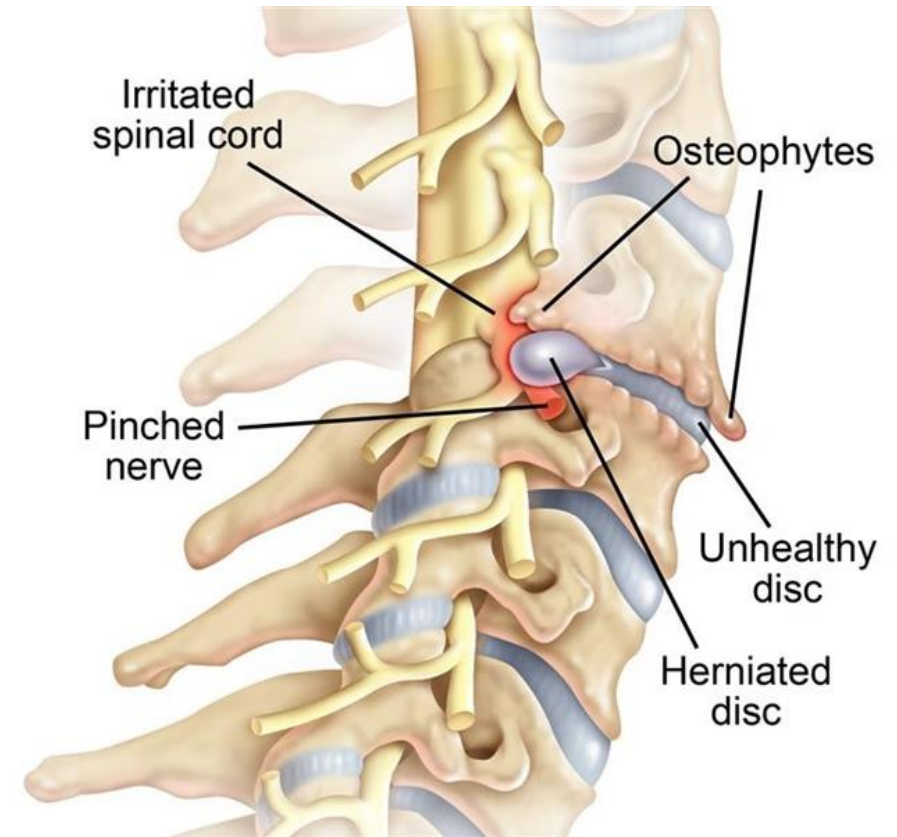
Cervical Radiculopathy

- Compression of a cervical nerve root
- Symptoms:
 - Arm pain, tingling, numbness, weakness
 - Generally travels from the neck to the arm or hand
 - May also feel pain in the shoulder, shoulder blade or upper back

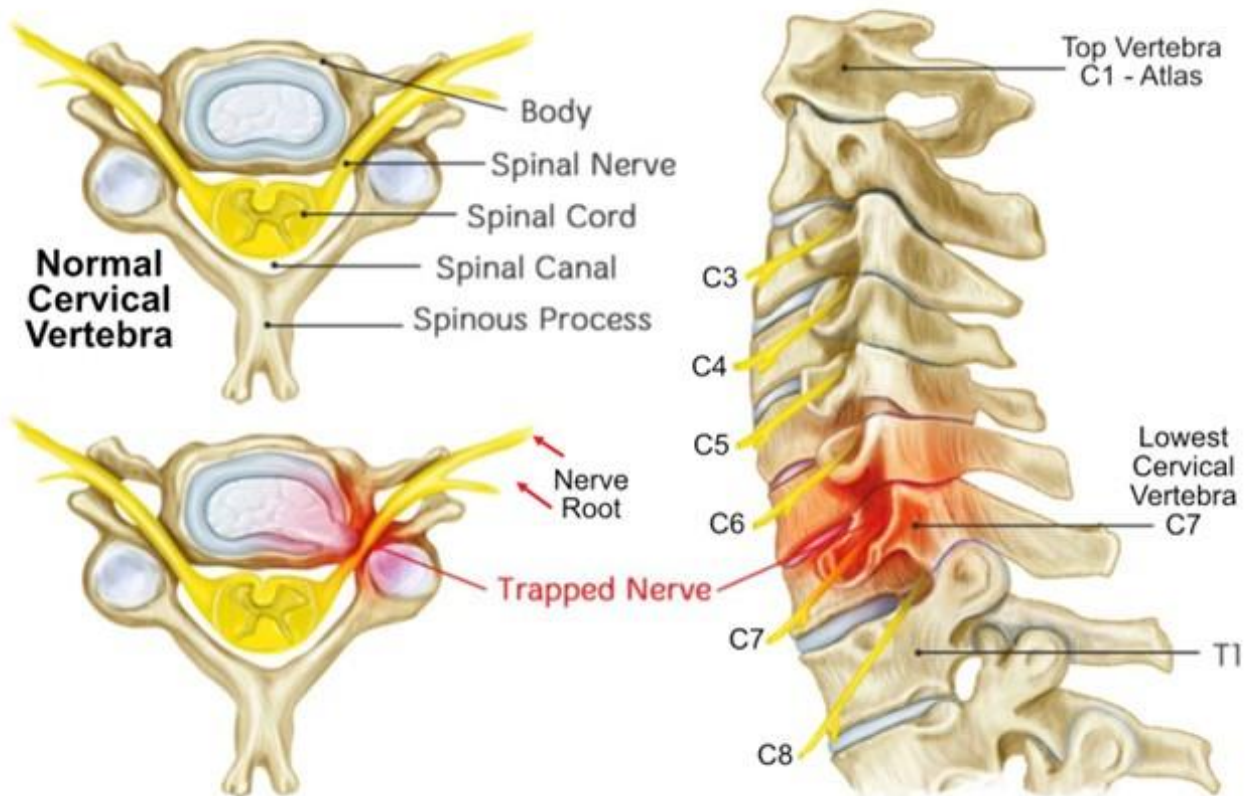


Cervical Radiculopathy

- Compression of a cervical nerve root
- Symptoms:
 - Arm pain, tingling, numbness, weakness
 - Generally travels from the neck to the arm or hand
- Causes:
 - Cervical disc herniation, foraminal stenosis (pinching of the nerve as it exits the spine)



Cervical Radiculopathy and Cervical Spinal Nerves



Cervical Radiculopathy and Radiation of Pain in the arm.

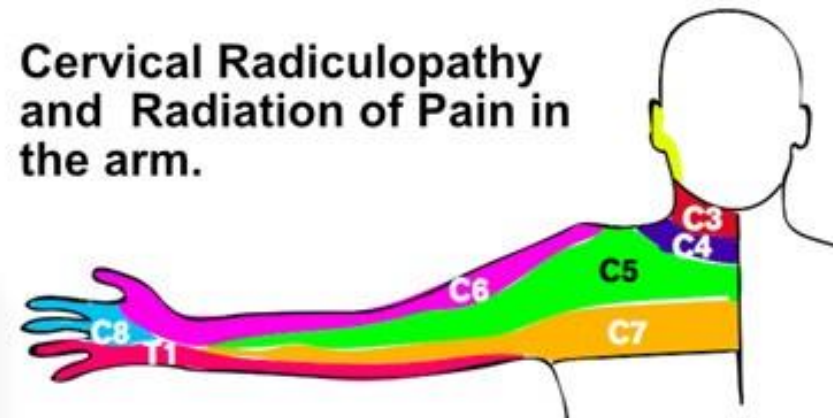
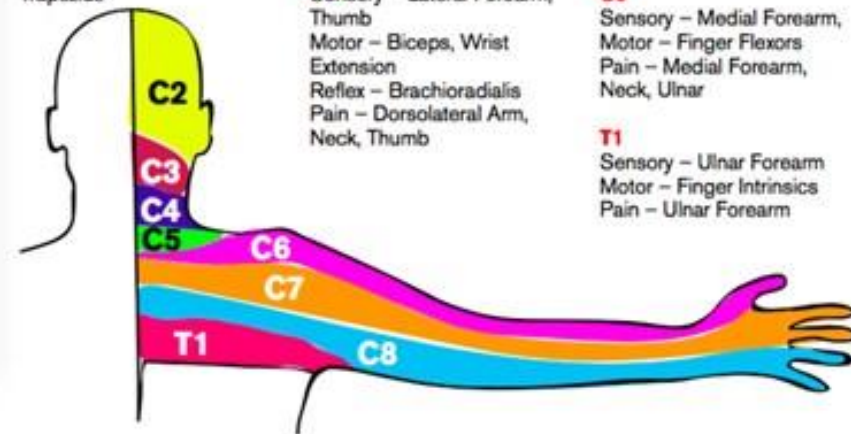
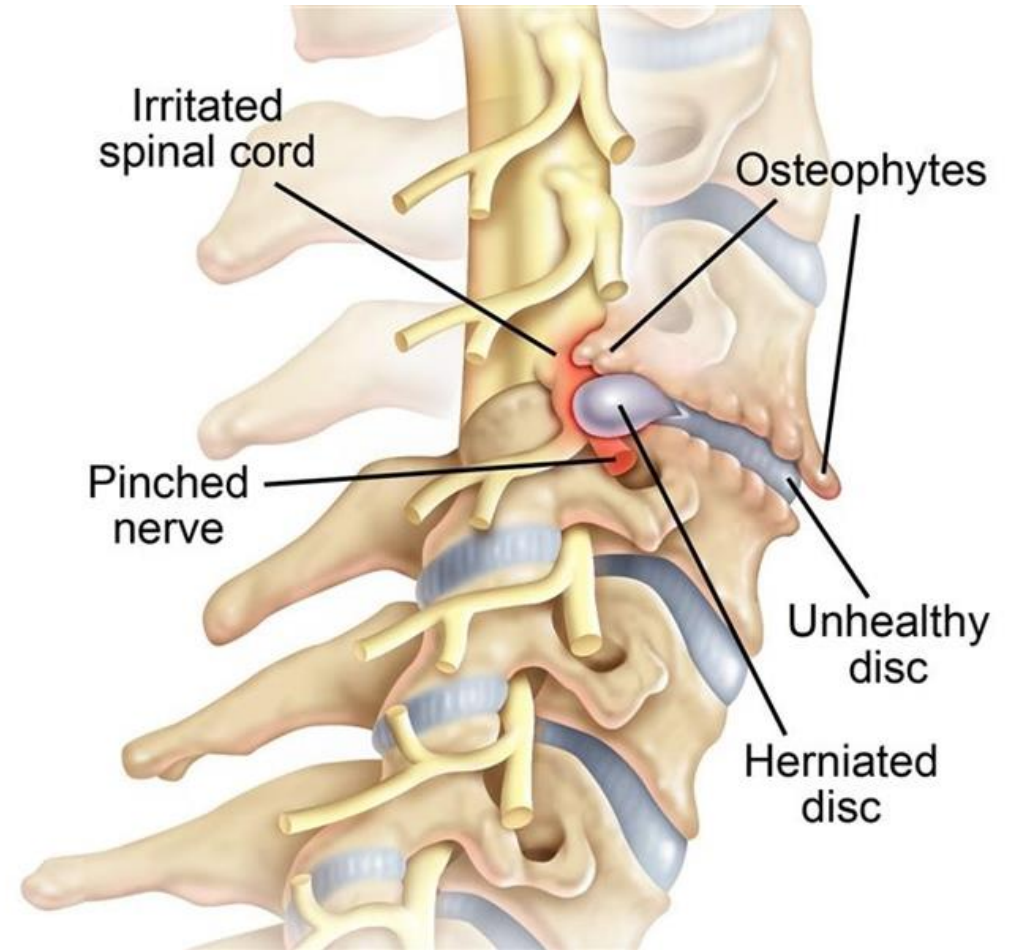


Figure 1: Manifestation of symptoms at different cervical nerve root levels

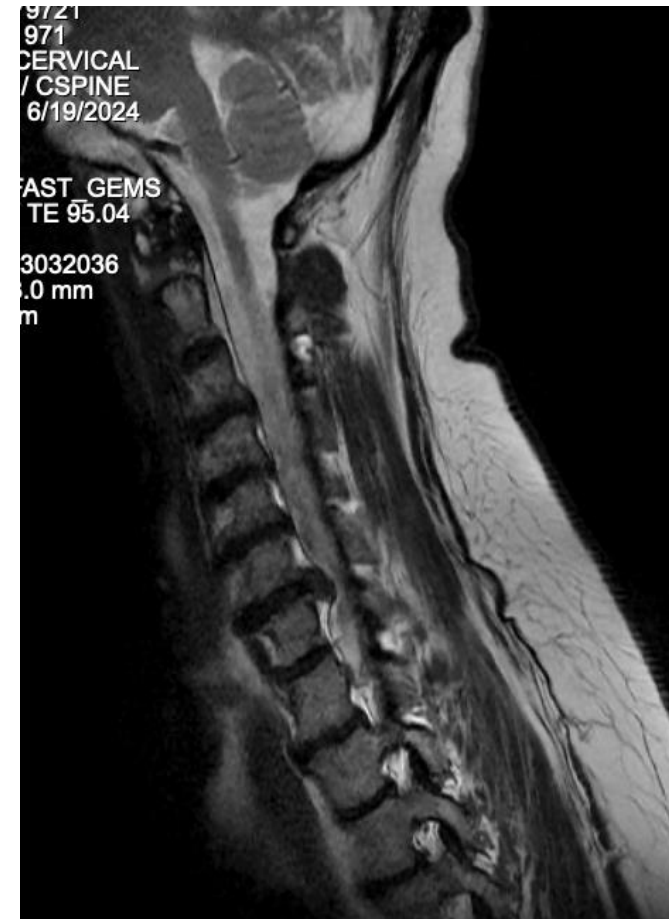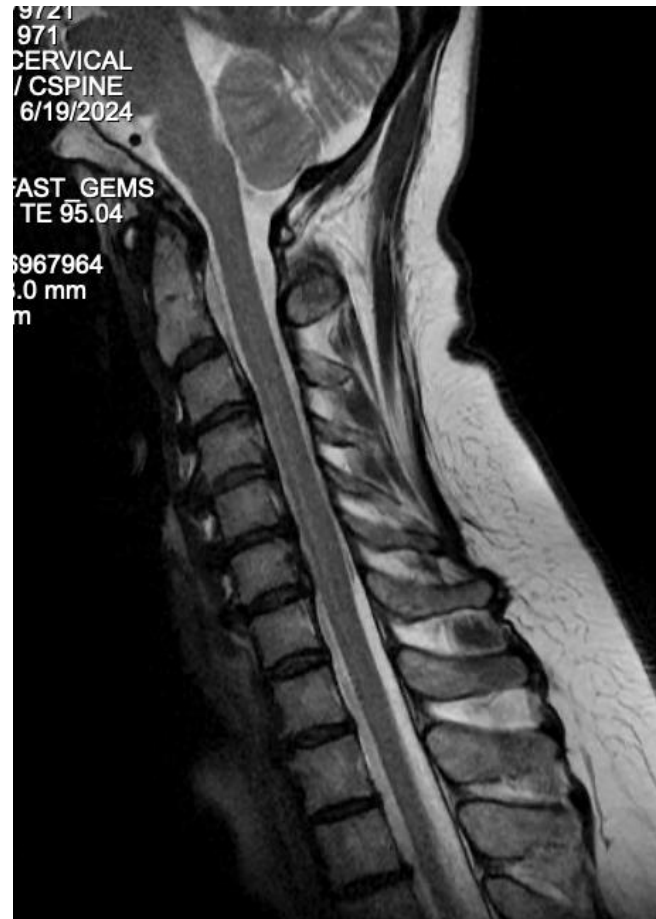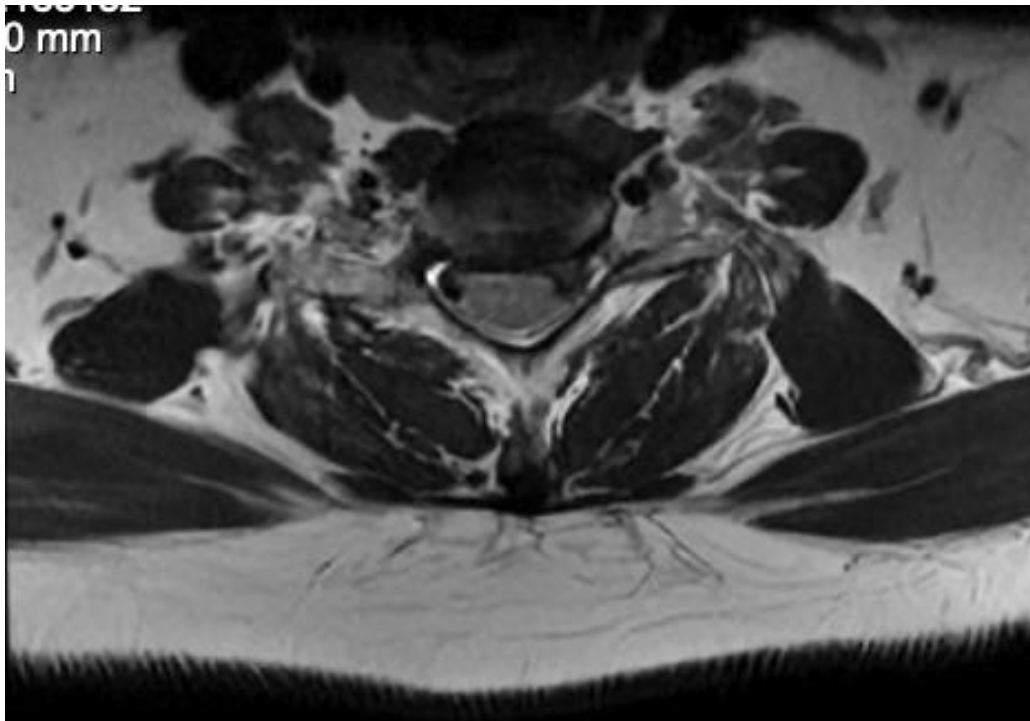
- | | | |
|--|--|---|
| C2
Pain – Headache, Eyes, Ears | C5
Sensory – Lateral Arm
Motor – Deltoid, Elbow Flexion
Reflex – Biceps
Pain – Lateral Arm, Neck, Shoulder | C7
Sensory – Dorsal Forearm, Index Finger
Motor – Triceps, Wrist Flexion
Reflex – Triceps
Pain – Dorsolateral Forearm, Middle Finger, Neck |
| C3
Pain – Neck, Trapezius | C6
Sensory – Lateral Forearm, Thumb
Motor – Biceps, Wrist Extension
Reflex – Brachioradialis
Pain – Dorsolateral Arm, Neck, Thumb | C8
Sensory – Medial Forearm, Motor – Finger Flexors
Pain – Medial Forearm, Neck, Ulnar |
| C4
Sensory – Cape distribution
Pain – Lower neck, Trapezius | | T1
Sensory – Ulnar Forearm
Motor – Finger Intrinsic
Pain – Ulnar Forearm |



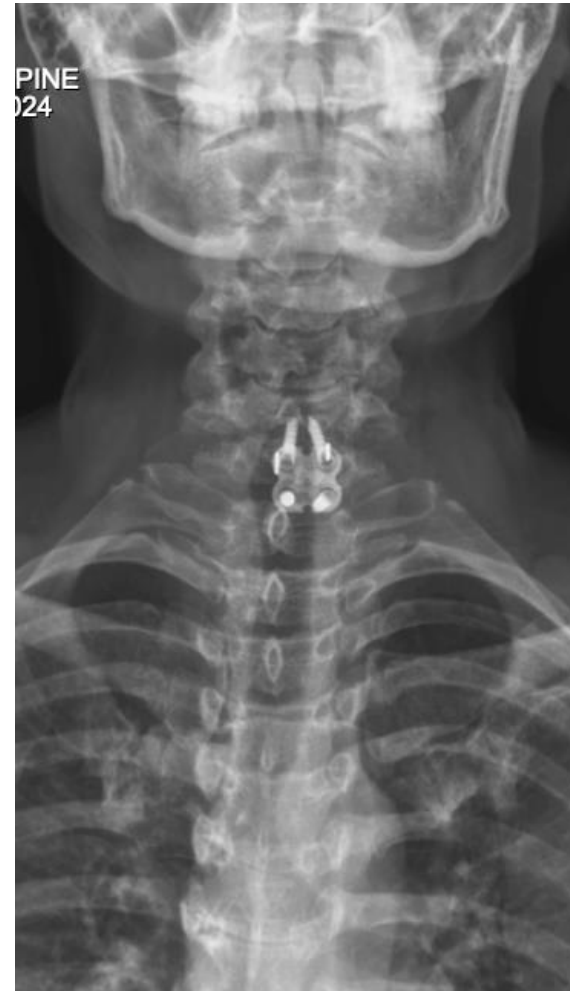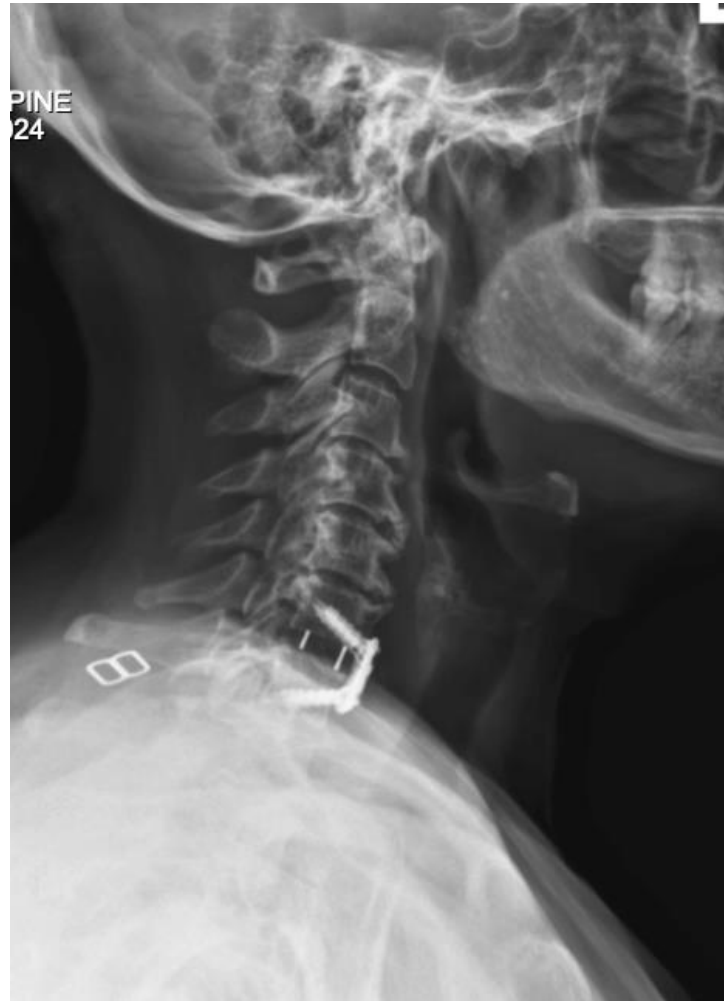- Treatments:
 - Rest, ice, heat, NSAIDS
 - Epidural steroid injections, gabapentin, oral steroids
 - Surgery



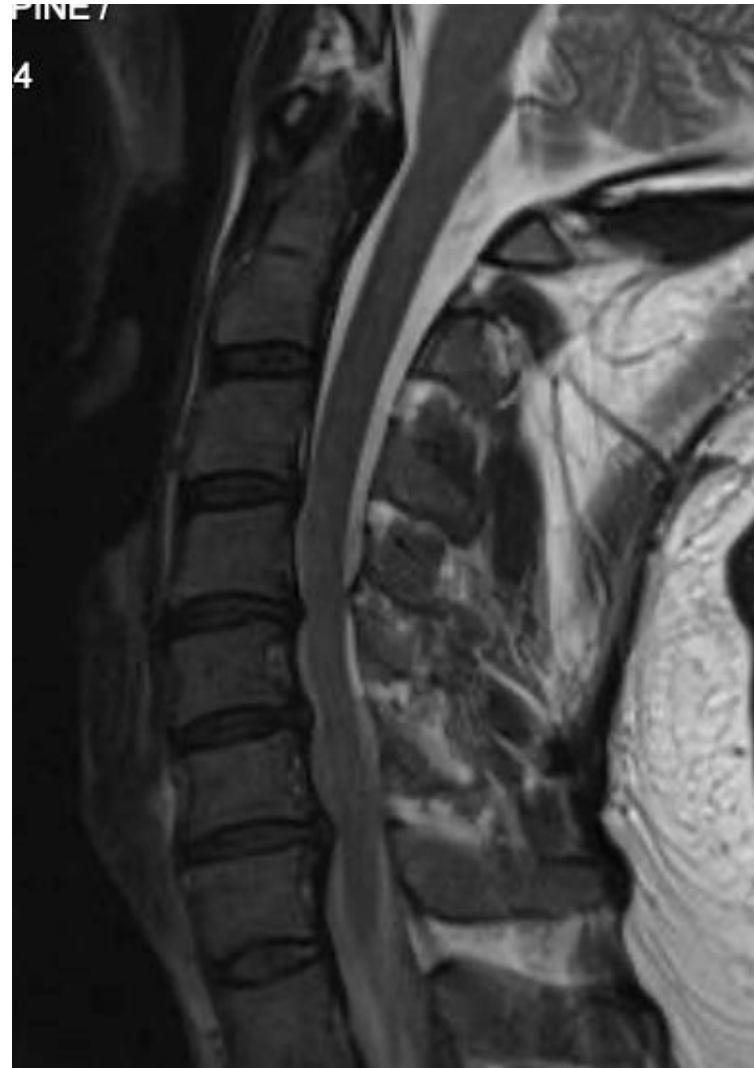
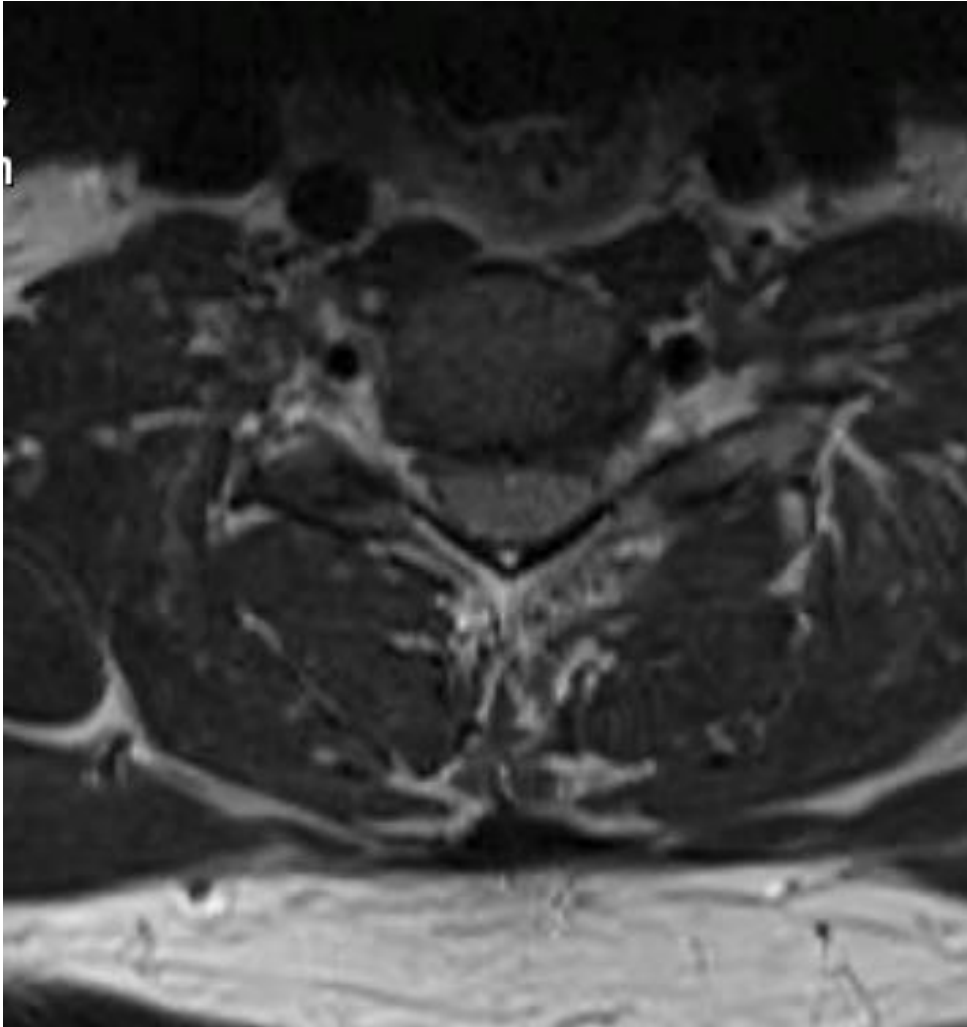
Cervical Radiculopathy



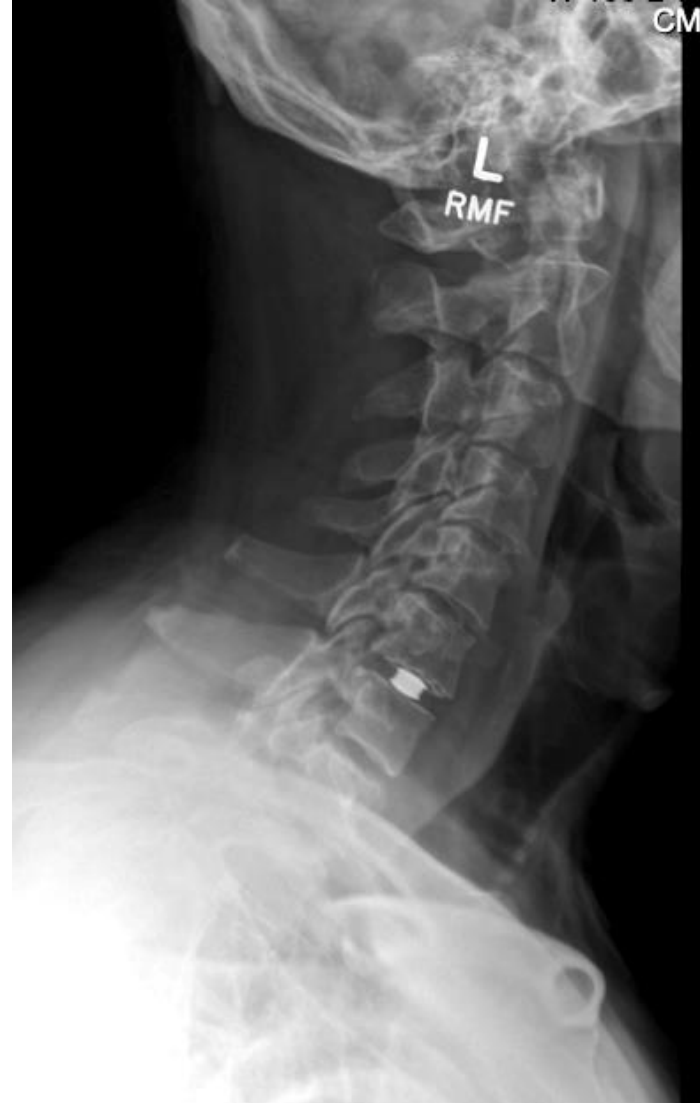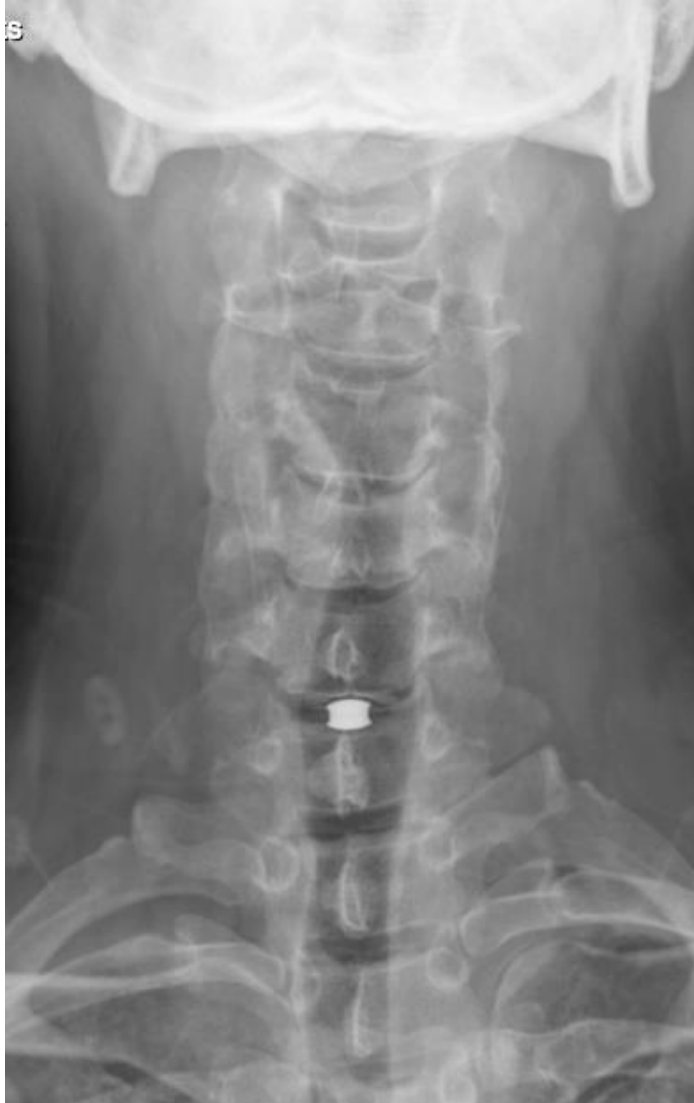Cervical Radiculopathy



Cervical Radiculopathy

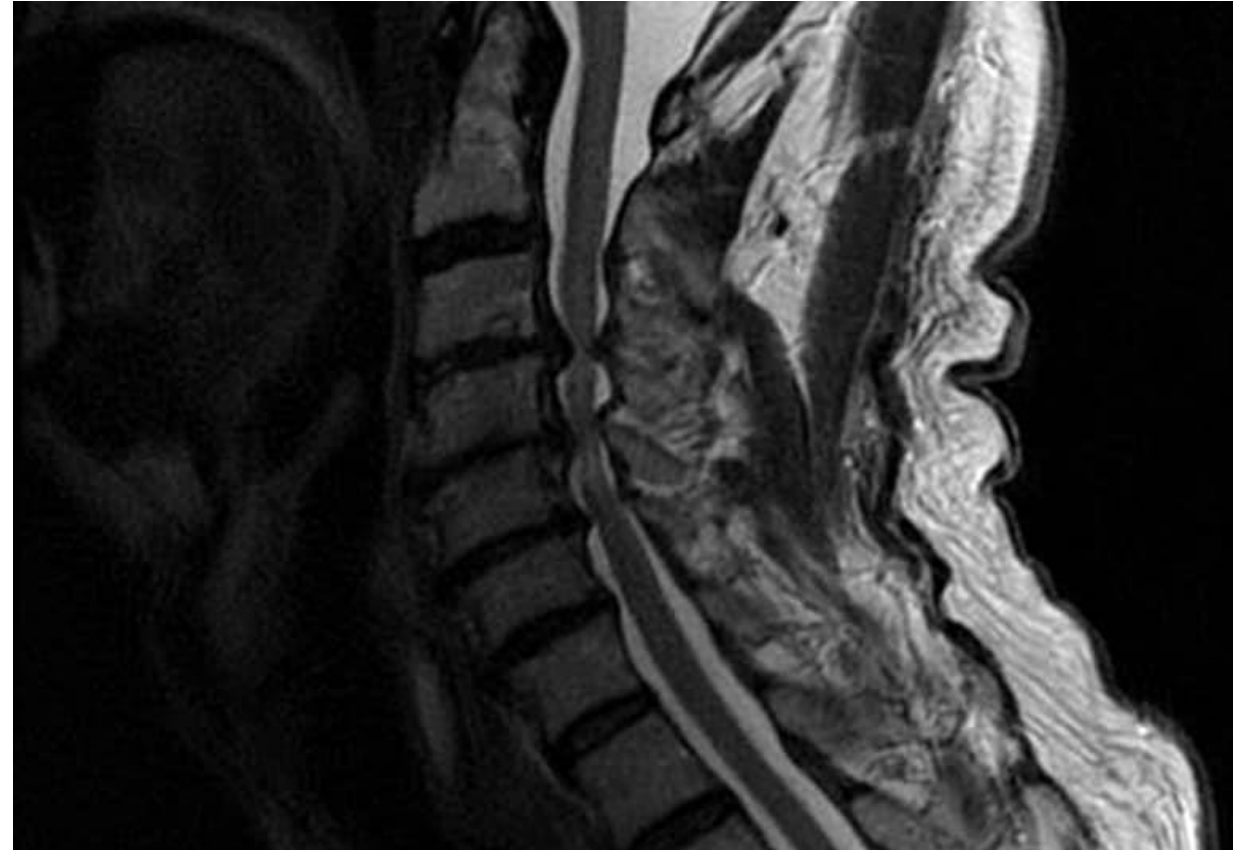

Cervical Radiculopathy



Cervical Myelopathy

- Severe cervical cord compression often due to degenerative change
- A chronic spinal cord injury
- Generally occurs gradually with a slow deterioration in function

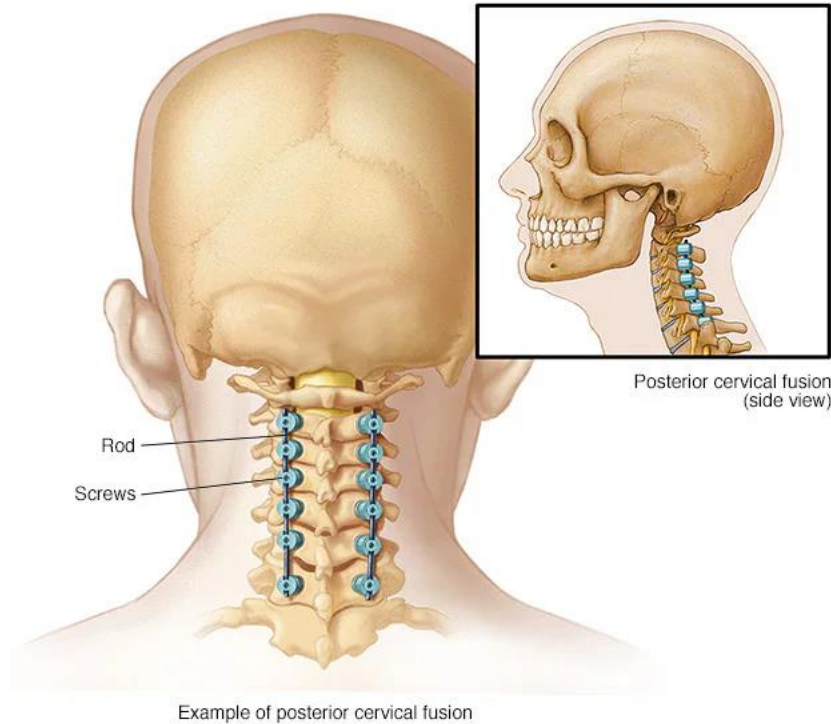
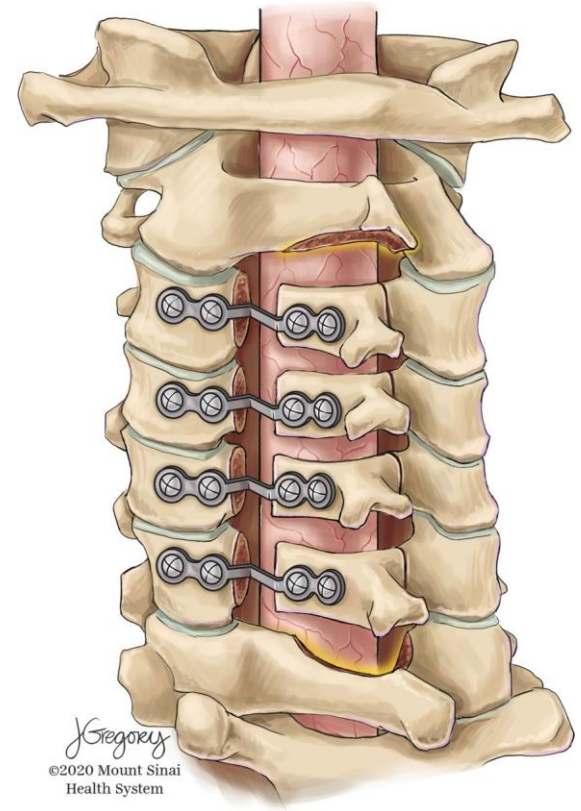
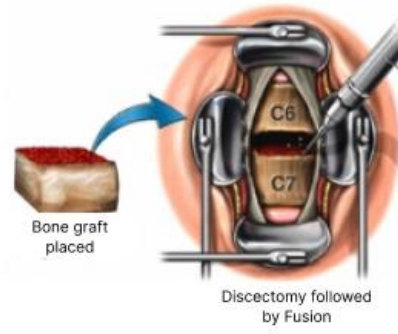
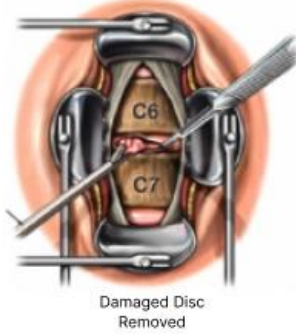
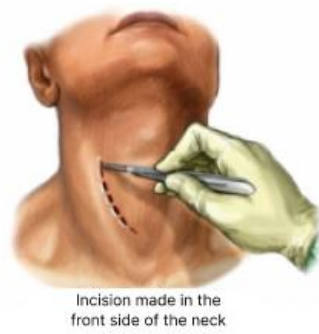
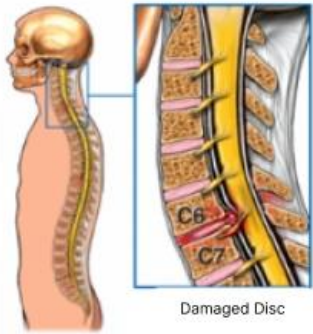

- Difficulty with balance “feel drunk”
- Trouble with hand fine motor tasks
- Upper and lower extremity numbness
- Hyperreflexia
- Weakness of arms and legs

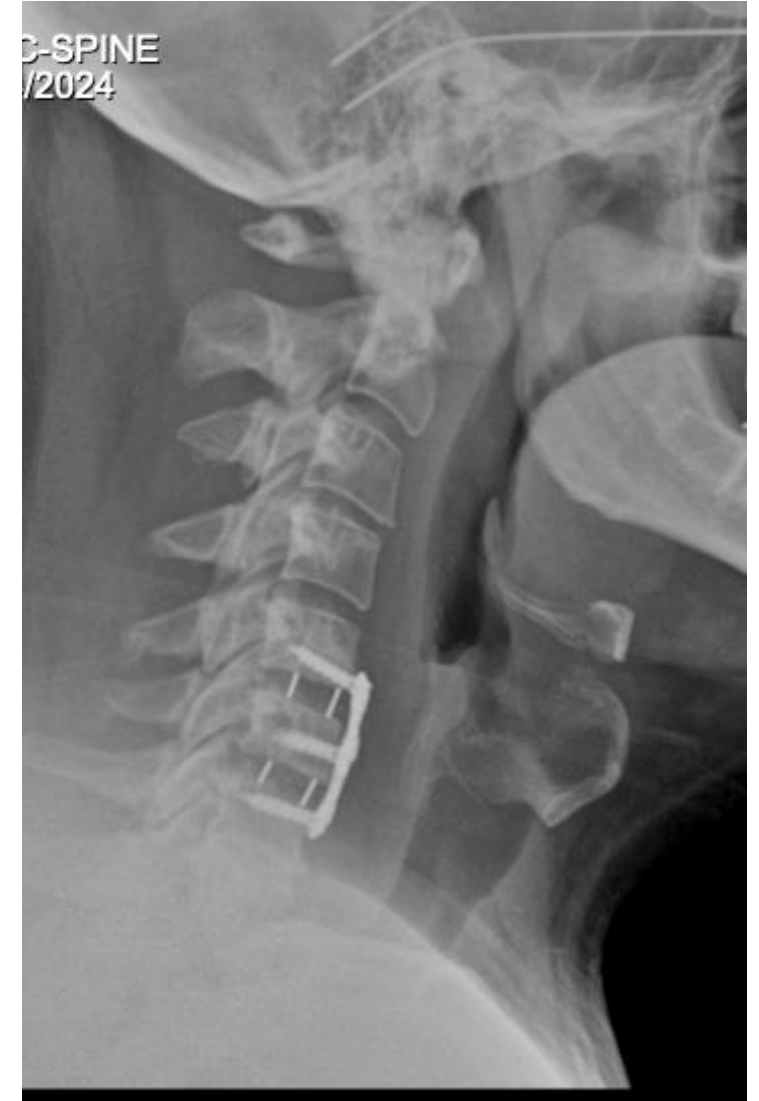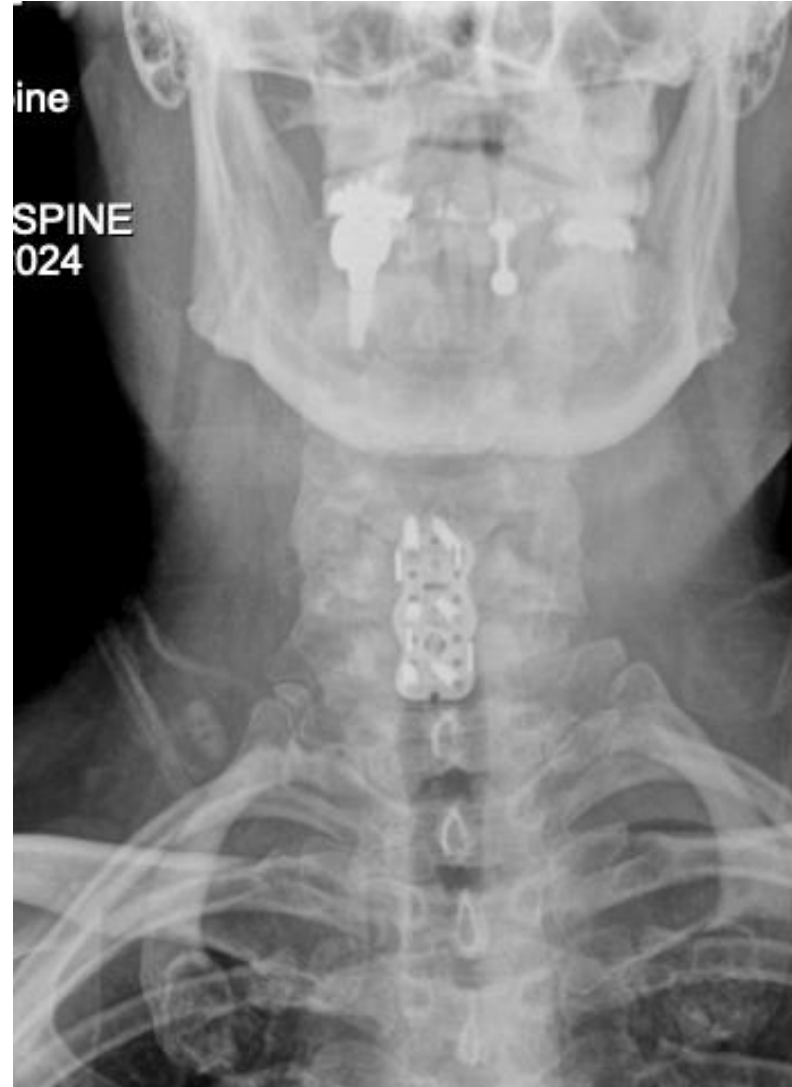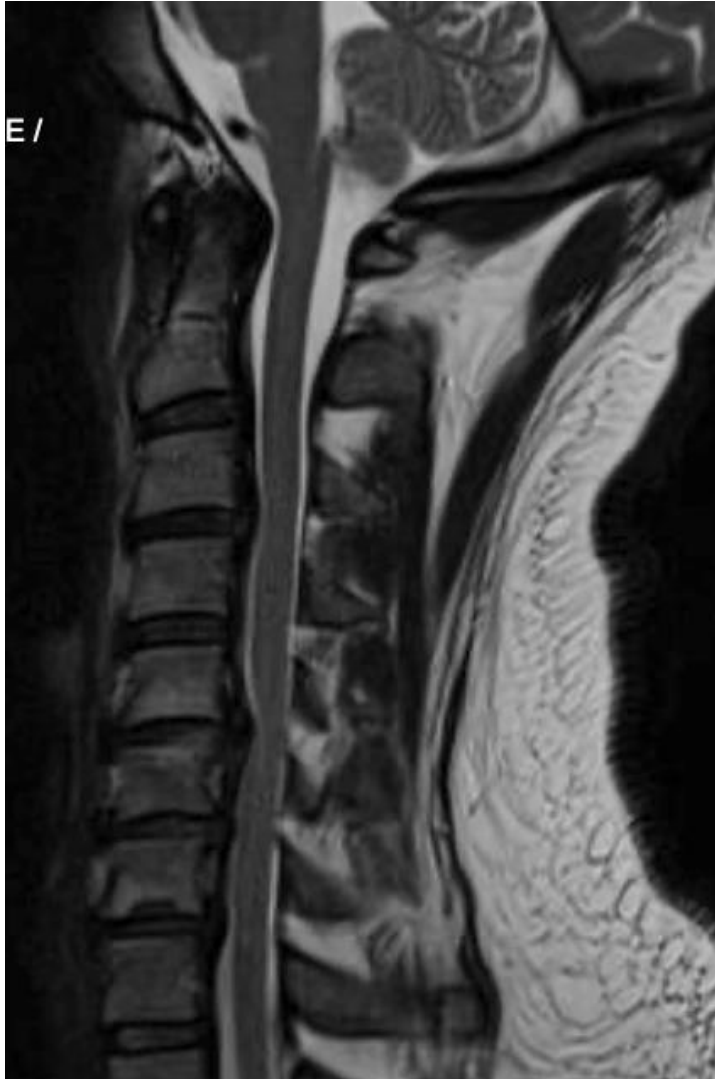- Mild disease traditionally managed conservatively
- New thinking is to operate early to avoid irreversible decline
- Moderate to severe disease needs surgery
- Surgery is designed to stop progression
- Some patients do improve

- Treatments:
 - ACDF
 - Posterior decompression and fusion
 - Laminoplasty
 - Anterior/Posterior

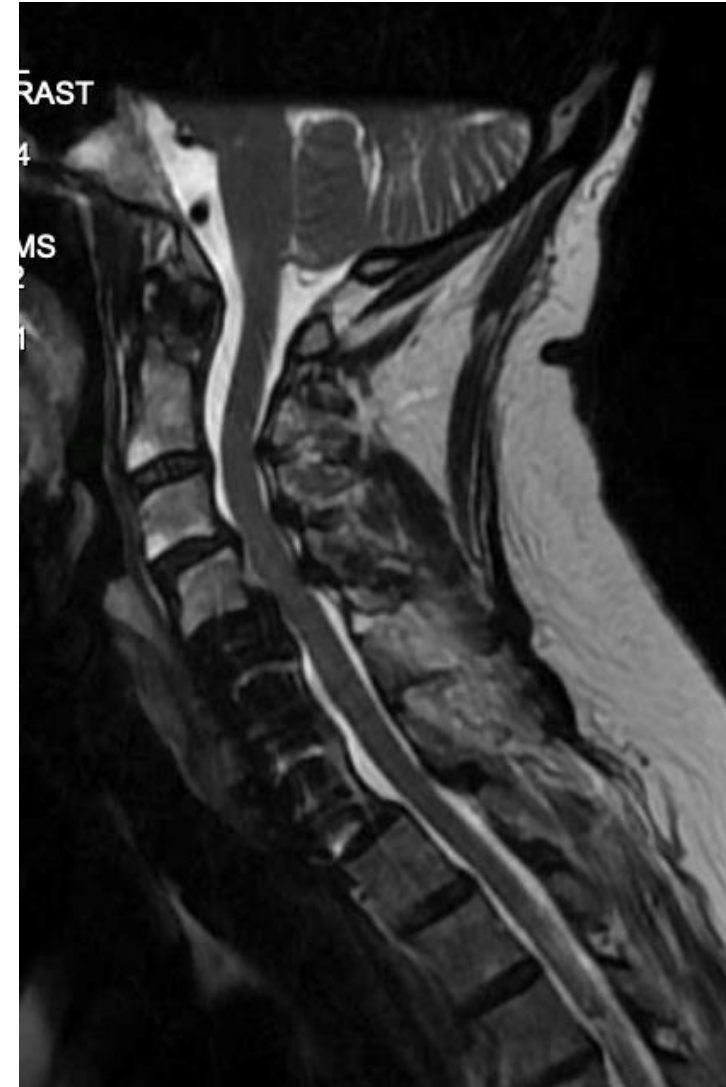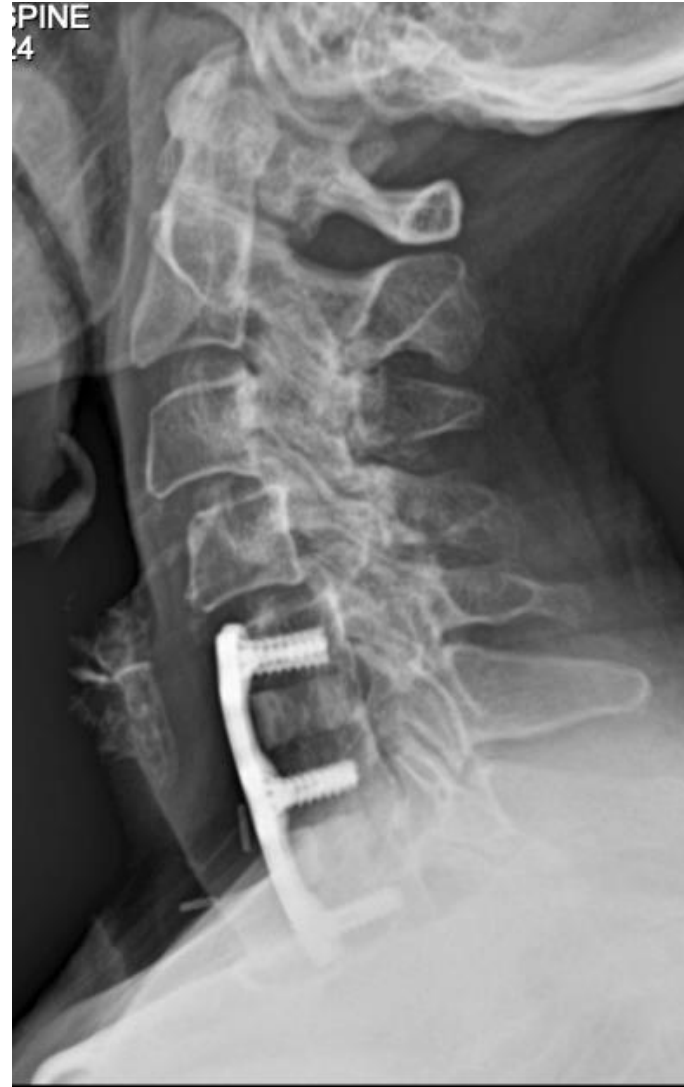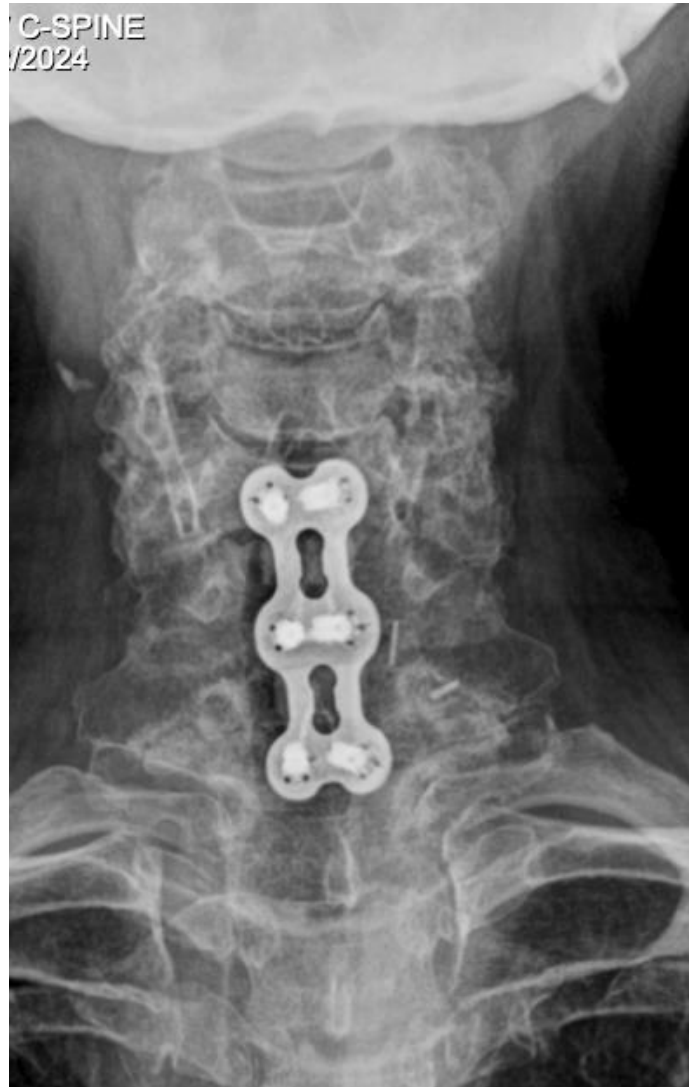Anterior Cervical Discectomy with Fusion (ACDF)



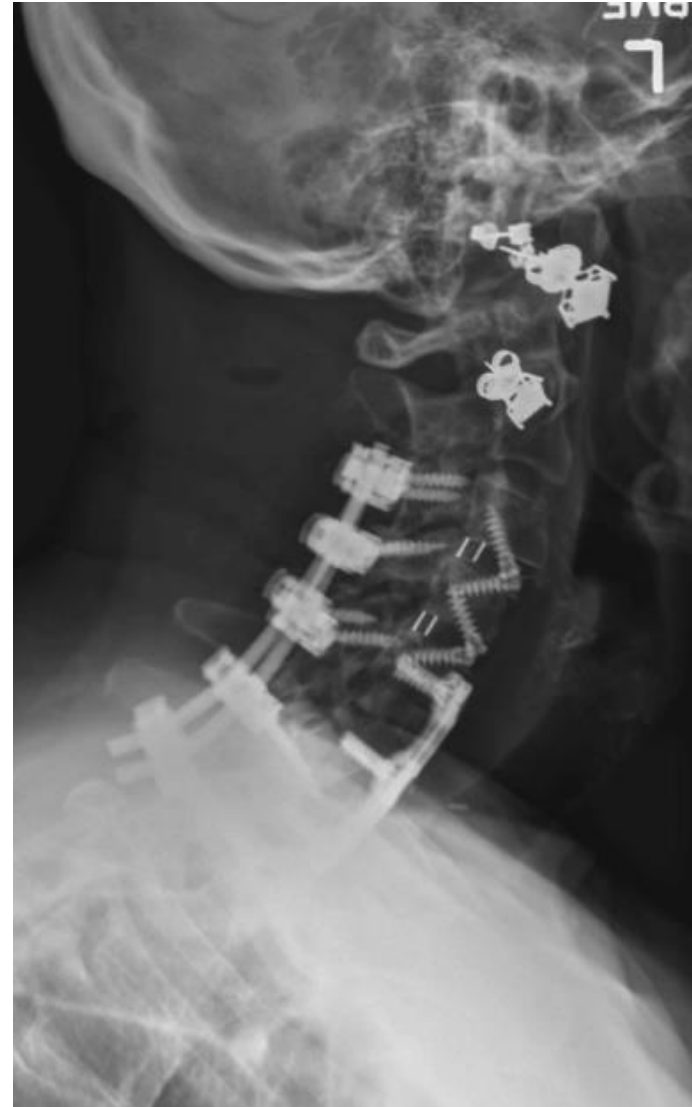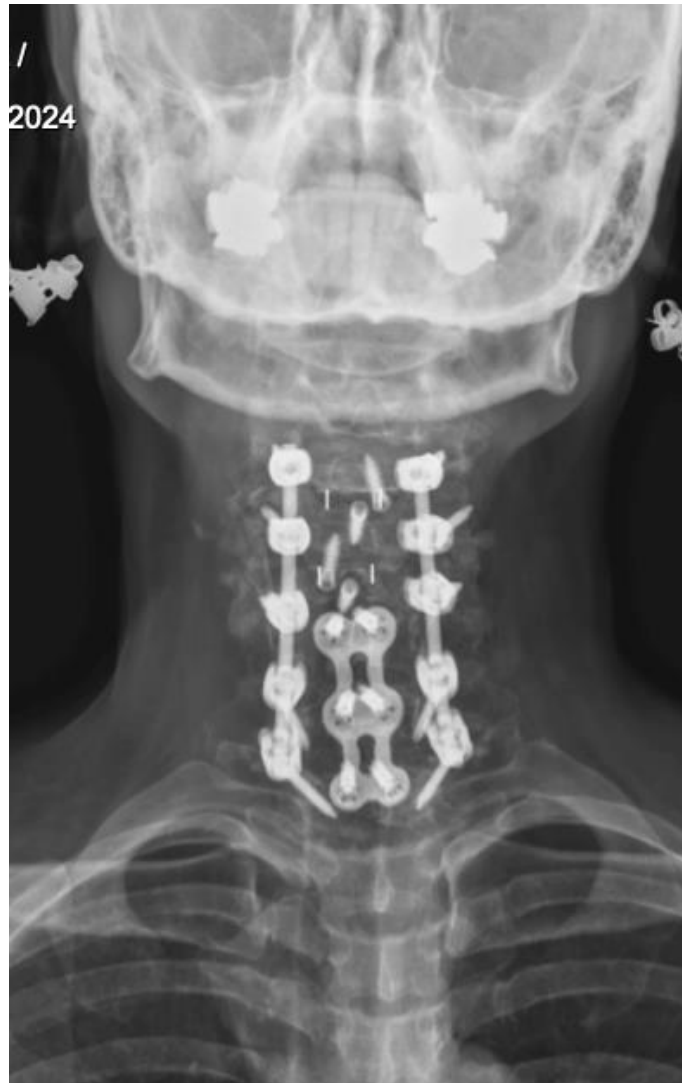Cervical Myelopathy

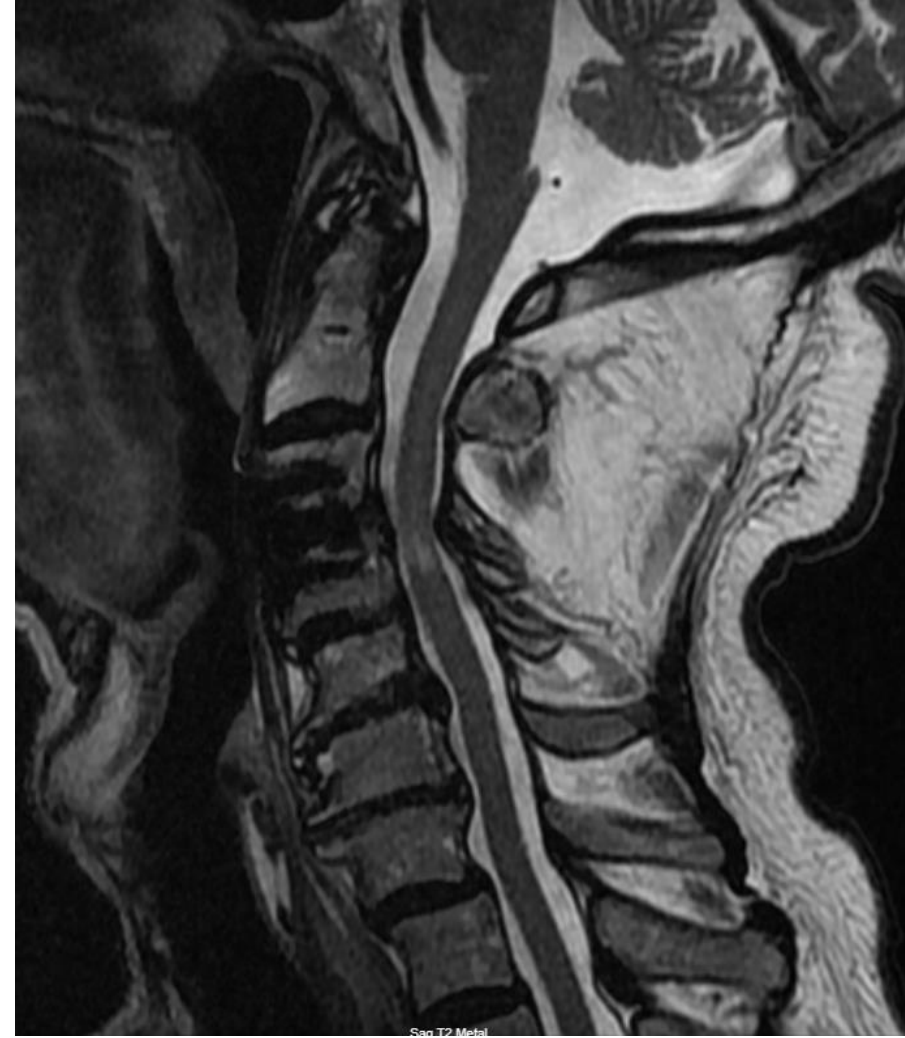
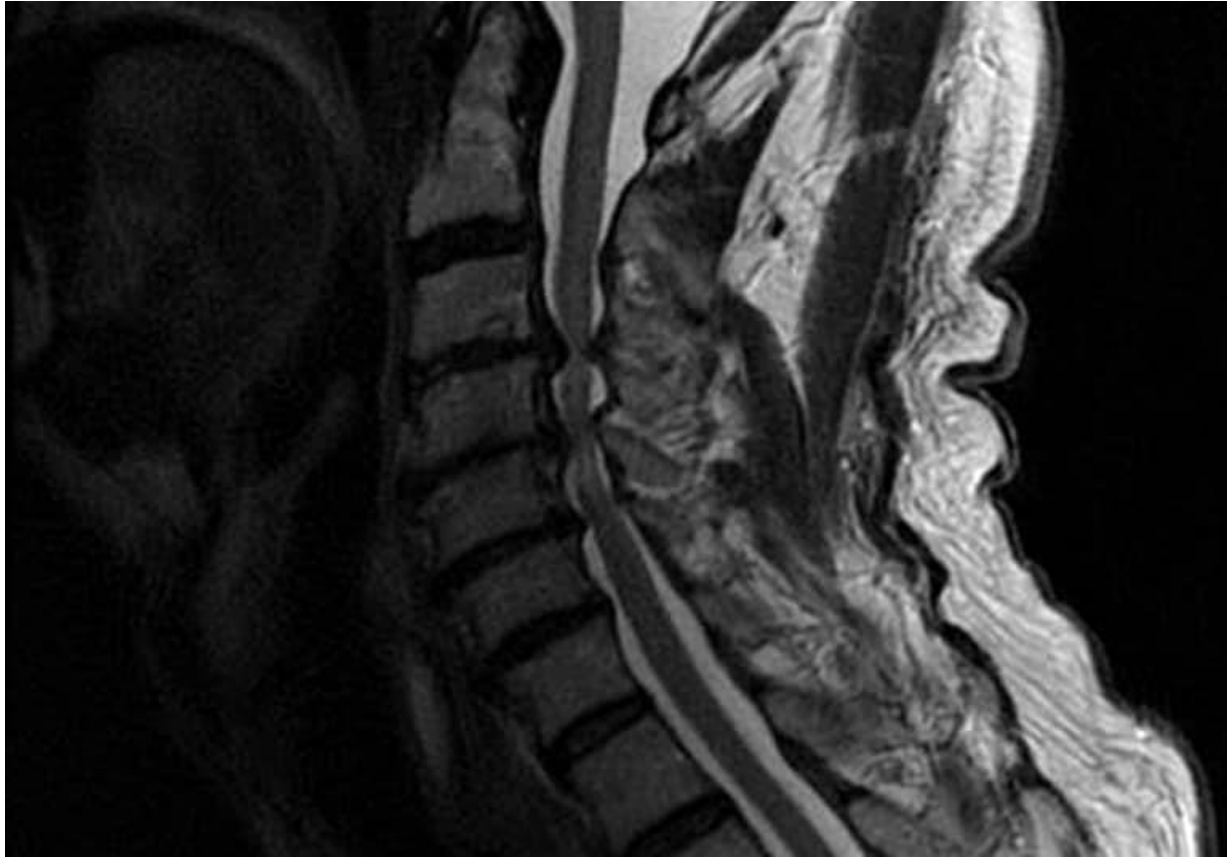
Cervical Myelopathy



Cervical Myelopathy





Relieving Painful Cervical Spine (neck) Problems

Robert Harper, MD
BoulderCentre for Orthopedics & Spine
720-442-0419

